

The Perspective

Look at our Dentists

FEATURED CASE: Dr. Amit Kamat Complete Denture Impressions



The dental literature is full of various complete denture impression techniques using various materials. The concept of selective pressure combines the principles of both pressure and non-pressure procedures. The nonstress-bearing areas are recorded with the least amount of pressure, and selective pressure is applied to certain areas of the maxillae and mandible that are capable of withstanding the forces of occlusion. These impressions are made in trays that have been "selectively"

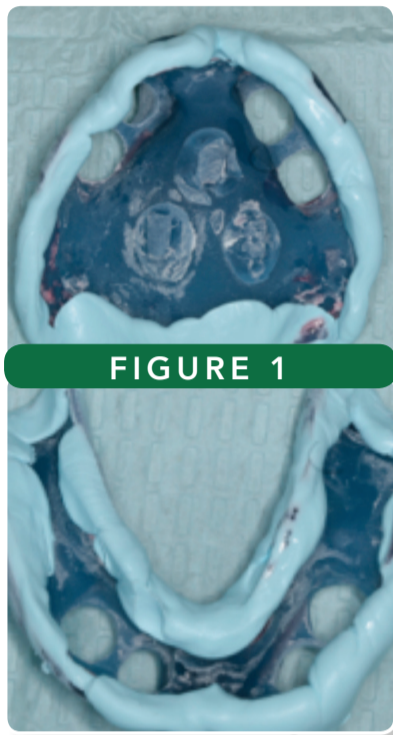


FIGURE 1

Figure 1: Custom trays border molded in VPS occlusal registration material before being trimmed

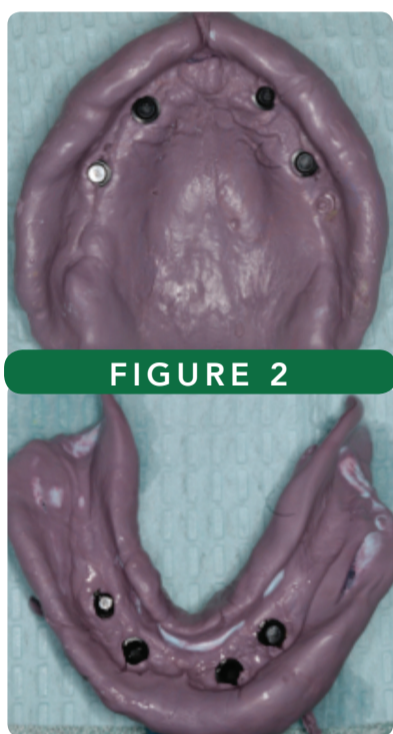


FIGURE 2

Figure 2: Final impressions in medium body VPS

relieved, therefore providing more space in some areas (wax spacer) while at the same time having areas within the tray that have less space. The places that have less space or relief will transmit more pressure during the impression. Ideally, this will then distribute a greater force during function to a more favorable part of the ridge/bone (Maxilla: Tuberosities, Mandible: Buccal Shelf) and less pressure to unfavorable parts (Anterior region of the maxilla and mandible). One way to achieve this is the following 1) Try in your custom tray and relieve the borders, 2) Apply VPS adhesive to the border, 3) Border mold the trays in sections with heavy body impression material or medium body occlusal registration material (Figure 1), 4) Trim the border molding back by 1mm, 5) Use a #8 round bur and selective relieve the anterior maxillary and mandibular regions of the tray, 6) Apply VPS adhesive throughout the tray, and 7) Make the final impression with medium body VPS material with finger pressure applied to the maxillary tuberosity region or mandibular buccal shelf region. (Figure 2).

Dr. Amit Kamat DMD, MS, FACP, Prosthodontist
Diplomate of the American Board of Prosthodontics.

PASSION FOR DENTISTRY EXPRESSED THROUGH MENTORING OTHERS AND BUILDING COMMUNITY

by Nick Azzara

Greenberg dentists took part in two great social outreach events in Tampa and Jacksonville this October. First, Wednesday, October 11th, a contingency of Greenberg doctors, Drs., Connie Feng, Shane Eckels, Aaron Goodwin, Michael Caputo, Quyen Pham, joined Dr. Barrett, and myself at a Pre-Dental Society meeting at the University of South Florida, to share their personal journeys and advice with the 30 plus club members. Many of our doctors were officers of their PDS and ASDA chapters and had valuable insights to share. Dr. Barrett commented, "I could not have been prouder of how our team was so quick to support and encourage these aspiring dentists." In Tampa, Thursday October 12, the Specialist in Jacksonville lead by Dr. Victor Yeung, (Periodontist, Partner) coordinated a Social Mixer at Moxie's Kitchen in the St. John's town center. The evening was a great opportunity for our specialist and general dentist to further solidify their working relationships, to maximize the benefits of our Multidisciplinary model, and help idealize coordinated patient care. It was also a great opportunity to welcome Dr. Michael Freeman to Jacksonville. Dr. Freeman recently relocated from our East Colonial office in Orlando to the Normandy office.



Nick Azzara, DNS Consulting Inc., Lab and Clinical Consultant to Greenberg Dental

Insights From Some of Our In-House Specialty Support

PEDIATRIC PERSPECTIVE

by Dr. Lenee Harrell



The American Academy of Pediatric Dentistry advises children establish a dental home as early as 12 months of age. Most general dentists likely will not want to see children this young, but it is important to advise parents that our in house pediatric specialists are available to help. With the introduction of silver diamine fluoride many young children can avoid sedation and have minimal caries arrested in office via this non-operative procedure. The pediatric specialists at Greenberg can also be a valuable resource for older children who might be unmanageable in your operatory. The pediatric dentists are well trained in behavior management and also can offer nitrous oxide as an effective analgesic/anxiolytic agent. If parents are concerned about esthetics let them know some of our pediatric specialists now offer tooth colored zirconia crowns for both anterior and posterior teeth. These are a durable, strong, cosmetic alternative to the traditional stainless steel crown. As a general dentist, you have the skills and knowledge to manage and treat many of these small patients but never feel you have to stretch yourself beyond your comfort level. Any questions regarding treatment, reach out to your pediatric dentist colleague, they are here to help.

Dr. Lenee Harrell DMD, Pediatric Dentist.

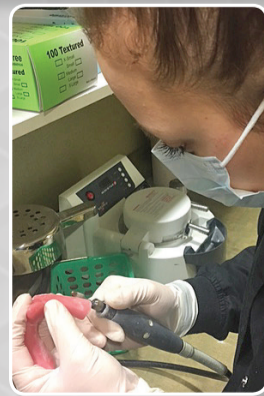WELCOME DR. SILVINA RAJSCHMIR

by Nick Azzara

Dr. Rajschmir comes to us with more than 15 years of experience as a prosthodontist in Argentina, as well as a Denturist, and instructor (George Brown College, Toronto) in Canada. Together with a very talented support staff, we welcome Dr. Rajschmir's Prosthodontic knowledge to help support complex case management and removable prosthesis for our offices in the Jacksonville area. Dr. Rajschmir is practicing in the Bartram office and is available for case consults and referrals.



Above: Dr. Rajschmir with her staff, Abby and Necci.



Right: Abby working on a custom tray.

Nick Azzara, DNS Consulting Inc., Lab and Clinical Consultant to Greenberg Dental

The Structure To Perform. The Team To Help. Let Us Help You Exceed Your Expectations.

We welcome your feedback or any questions!

DrBarrett@GreenbergDental.com